



Global Advanced Research Journal of Microbiology (ISSN: 2315-5116) Vol. 2(7) pp. 127-130, August, 2013  
Available online <http://garj.org/garjm/index.htm>  
Copyright © 2013 Global Advanced Research Journals

*Full Length Research Paper*

# Isolation, Identification and Therapeutic Management of Bacterial Mastitis in Jamunapari Goat in Hyderabad

**S. Ayodhya,**

Assistant Professor, Campus Veterinary Hospital, TVCC, College of Veterinary Science, Rajendranagar, Hyderabad, A. P.

Accepted 05 August, 2013

**Jamunapari goat was brought to the Campus Veterinary Hospital, Teaching Veterinary Clinical Complex, College of Veterinary Science, Rajendranagar with history of enlargement of udder. The confirmatory diagnosis was done by cultural examination of milk samples from mastitis goat revealed mixed infection of Staphylococcal spp., E. coli and Klebsiella spp. Antibiotic sensitivity test studies of mastitis milk samples from goat revealed more sensitivity to amoxicillin- clavulanic Acid antibiotic and the treatment was followed by injecting amoxicillin- clavulanic acid and dexamethasone and meloxicam . After 10 days therapy goat was completely recovered recorded as normal udder size, shape, temperature and recorded normal milk colour and increased production of milk.**

**Keywords:** Udder, Jamunapari Goat, Therapy, Antibiotic sensitivity test, Cultural Examinations

## INTRODUCTION

The nutritional components that make milk an important part of the human diet also support the growth of pathogenic microorganisms coming from milk contamination or from animal infections. Mastitis is the total or partial inflammation of the mammary gland provoked by one or more pathogenic microorganisms, which can appear either in clinical or subclinical forms (Bramley, *et al.* 1980). Mastitis is characterized by physical, chemical, and usually bacteriological changes in the milk and by pathological changes in the udder. The presence of microorganisms in milk usually can be demonstrated by microbial culture. *Staphylococcus* spp., *E.coli*, *Corynebacterium* spp. and *Klebsiella* spp. are the most frequently diagnosed microorganisms responsible for intramammary infection in goats and sheep's in which

*Staphylococcus* spp. causes severe form of mastitis (Arlington, *et al.*1990). Early recognition and prompt treatment are important for limiting tissue damage and production losses. However, since treatment is often unrewarding, emphasis should be on mastitis control and prevention (Smith, *et al.*1977).

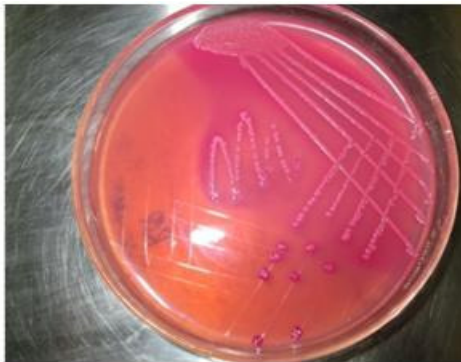## MATERIALS AND METHOD

The goat presented at Veterinary Hospital with history of enlargement of both two udder quarters was milked by a hand according to standard procedures. Prior to milking, goat teats were washed with clean tap water and dried with single service paper towel. After detection of mastitis by the California Mastitis Test (CMT), milk samples (10 ml) were collected in sterilized test tubes and were inoculated on to MacConkey's, EMB, nutrient broth and blood agar

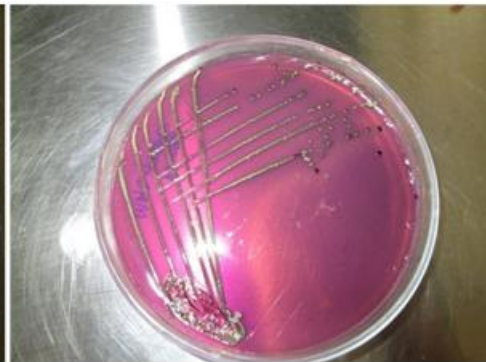\*Corresponding Author's Email: [sayodhya\\_6@yahoo.com](mailto:sayodhya_6@yahoo.com)



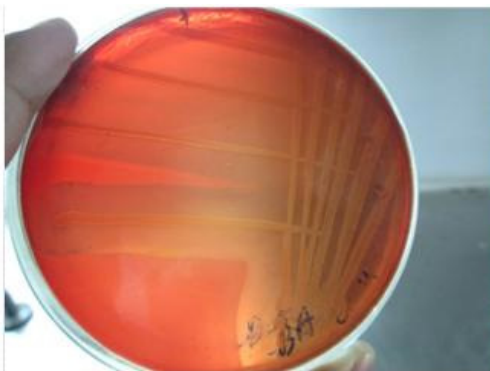
**Figure. 1** Jamunapari goat showing mastitis in Campus Veterinary Hospital, Hyderabad



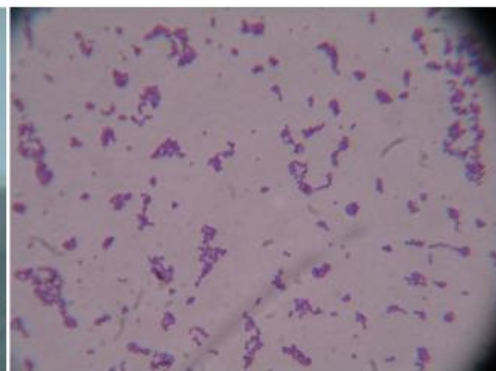
**Figure 2.** MAC- pink mucoid colonies (Klebsiella)



**Figure 3.** EMB black colonies with metallic sheen (E.coli)



**Figure 4.** Blood agar- Haemolysis (Staphylococcus)



**Figure 5.** Smears prepared from MSA- (Staphylococcus)

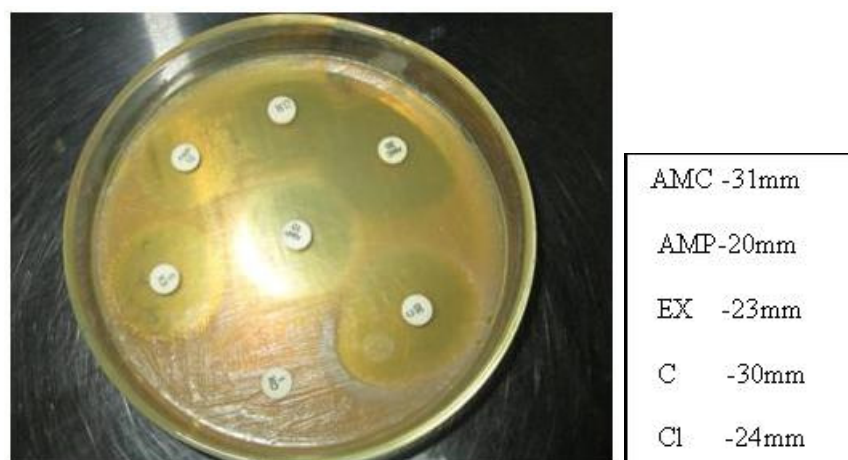


Figure 6. ABST Findings

plates. The bacterial isolates were identified on the basis of their cultural, morphological characteristics and biochemical reactions. For antibiotic susceptibility tests, Brain heart infusion (BHI) was used with Disc Diffusion Method.

## RESULTS AND DISCUSSION

Jamunapari goat was brought to the Campus Veterinary Hospital, Teaching Veterinary Clinical Complex, College of Veterinary Science, Rajendranagar with history of enlargement of udder since 15days, kidded one month back, decreased in milk production, painful, hotness and hard condition (except the teat canal) on udder palpation and observed dull, depression with inappetance since 10days. Examination of milk revealed slight discoloration and clots.

In the present study the confirmatory diagnosis was done by cultural examination of milk samples from mastitis goat revealed mixed infection of *Staphylococcal* spp., *E. coli* and *Klebsiella* spp.

Antibiotic sensitivity test studies of mastitis milk samples from goat revealed different sensitivities to various antibiotics viz., Amoxicillin- Clavulanic Acid (31mm), Chloramphenicol (30mm), Chlortetracycline (24mm), Enrofloxacin (23mm), Ampicillin (20mm), Therefore for more effective, Amoxicillin- Clavulanic Acid antibiotic was selected as a drug of choice for mastitis goat.

In the present case, the treatment was followed by injecting Amoxicillin- Clavulanic Acid (Intamox) @10mg/kg body daily for 10days by i/m route. Dexamethasone (Dexona) @ 4mg i/m once daily for 5 days as fibrolitic and meloxicam (Menonex) @ 0.2mg/kg body weight daily for 10 days by s/c to reduce the inflammation of udder.

Following therapy improvement was observed slowly day by day that was recorded as decreasing size of udder,

improving colour of milk, udder slowly becoming resilient on palpation and hotness of udder becoming to normal. After 10 days therapy goat was completely recovered recorded as normal udder size, shape, temperature and recorded normal milk colour and increased production of milk.

The therapy instituted in the present case is in agreement with Alawa, *et.al.*, (1996), Egwu, *et.al.*, (1994), Kawu, et al (1992), Bramley, et al (1980) and Smith, et al (1977) who reported the efficacy of Amoxicillin against mastitis in goats and Arlington, et al(1990), Addo, et al (1980), Akinsoyinu, et al(1982), Blood, et al (1989), Carter, et al (1973), Chineme, et al(1984), Luna, et al (1968) Murphy, et al (1941) Twiwo et al (1985), who reported that various diagnostic methods for mastitis in goats and animals.

## ACKNOWLEDGEMENTS

Author acknowledges the Assistant Professor, Campus Veterinary Hospital, Teaching Veterinary Clinical complex and Professor and Head, Department of Microbiology, College of Veterinary Science, Rajendranagar, Hyderabad for allowing for research and for the sample collection.

## REFERENCES

- Addo PB, Chineme CN, Eid FIA (1980). Incidence and importance of chronic mastitis in Nigerian goats. Bull. Anim. Hlth. Prod. Afr. 28(3): 225±231.
- Akinsoyinu AO, Tewe OO, Ngere LO, Mba AU (1982). Milk composition and yield of the Red Sokoto (Maradi) goats in Nigeria. Dairy Sci. Abstr. 43, 83±84.
- Alawa JP, Ngele MB, Ogwu D (1996). A survey of udder and teat abnormality in indigenous breeds of goats. Nig. J. Agric. Ext. 10, 50±59.

**130. Glo. Adv. Res. J. Microbiol.**

- Arlington VA, Carter GR, Cole JRJ (1990). Diagnostic procedures in veterinary bacteriology and mycology. Essentials of veterinary bacteriology and mycology. 5<sup>th</sup> Ed. Academic press, USA.
- Blood DC, Radostits OM, Henderson JA (1989). Veterinary Medicine, 7th ed. ELBS]
- Bramley AJ, Dodd FH, Grifon TK (1980). Mastitis Control and Herd Management. Technical Bulletin No.4. NIRD, Reading, England and Hannah Research Institute, Ayr, Scotland. Schalm, O.W., 1977. The bovine mammary gland: structure and function. J. Amer. Vet. Med. Assn. 170, 1137±1140.
- Carter GR (1973). Diagnostic Procedures in Veterinary Microbiology, 2nd ed. C.C. Thomas, Springfield Ill, USA.
- Chineme CN, Addo PB (1984). Chronic caprine mastitis: Clinical, microbiological and pathological findings in spontaneously occurring cases in Nigerian goats. Int. Sheep and Goat Res. 2, 266±273.
- Egwu CO, Zaria LT, Onyeyili PA, Ambali AG, Adamu SS, Birdling M (1994). Studies on microbiological flora of caprine mastitis and antibiotic inhibitory concentrations in Nigeria. Small Rumin. Res. 14, 233±239.
- Kawu MU, Umoh JU, Adekeye JO, Kwanashie C (1992). Prevalence and seasonal variation in the occurrence of clinical mastitis in small ruminants in Zaria, Nigeria. Paper presented at the 29th Annual Conference of the Nigerian Veterinary Medical Association, Durbar Hotel, Kaduna, 27±30 October, 1992.
- Luna LG (1968). Manual of histologic staining methods of the Armed Forces Institute of Pathology, 3rd ed. McGraw-Hill, New York.
- Murphy JM, Hanson JJ (1941). A modified Whiteside test for the detection of chronic bovine mastitis. Cornell Vet. 31, 47±55.
- Smith MC, Roguinsky M (1977). Mastitis and other diseases of the goats udder. J. Amer. Vet. Med. Assn. 171, 1241±1246.
- Tiwio BBA, Buvanendran V (1985). Evaluation of indigenous breeds of sheep and goats. I. Importance of heredity in the causation of udder and teat abnormality. Research Progress Report, p. 14. National Animal Production Research Institute, Zaria, Nigeria.